Cardiac MRI Essentials

Atrial septal defect

- In cases of ASD, CMR provides valuable information on:
  - Defect location, size, and anatomy
  - Right and left atrial size
  - Right ventricular size and function
  - Evidence of volume/pressure overload
  - Shunt calculation
  - Anomalous pulmonary venous drainage.

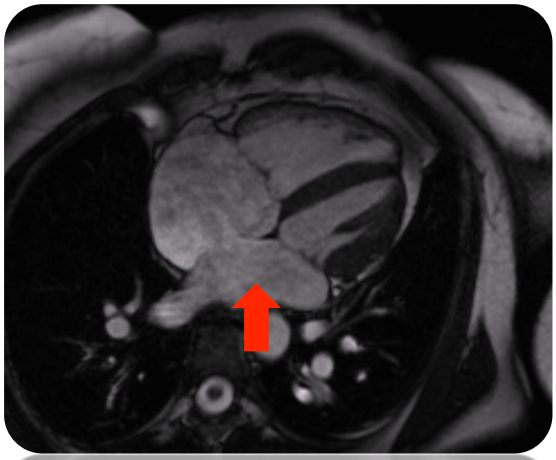

Secundum ASD: 4-chamber view

- Shows evidence of a defect in the interatrial septum
- Also shows right heart dilatation in keeping with volume overload

Secundum ASD: Short axis view

- Shows evidence of a secundum atrial septal defect with left-to-right flow

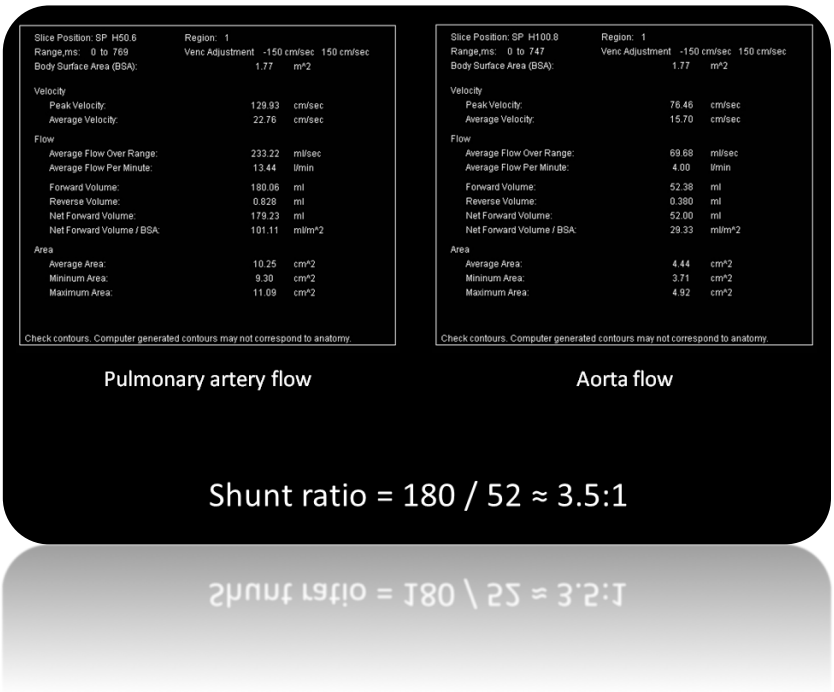

CMR allows quantification of the shunt ratio, from flow volumes in the pulmonary artery and aorta

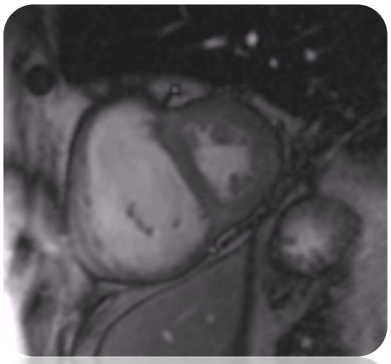

Pulmonary hypertension

- In patients with pulmonary hypertension secondary to ASD, a D-shaped left ventricle (due to septal flattening) is evidence of right ventricular pressure overload

How do we assess VSD with CMR?

CMR assessment in atrial septal defect should include:

- Description of ASD type, size, and location
- Description of left and right atrial size
- Quantification of right ventricular size and function
- Assessment of evidence of volume/pressure overload
- Flow assessment (shunt ratio)
- Description of pulmonary venous connections.

Further reading

EACVI CMR Pocket Guide: Congenital Heart Disease (2014) [click here to access online]